

# Primary Epithelioid Angiosarcoma of Spleen: A Case Report and Review of Literature

RANIA ABDALLAH ABDALLAH<sup>1</sup>, ASMAA GABER ABDOU<sup>2</sup>, NANCY YOUSEF ASAAD<sup>3</sup>, DALIA RIFAAT AL-SHARAKY<sup>4</sup>, ALSHIMAA MAHMOUD ALHANAFY<sup>5</sup>

## ABSTRACT

Splenic angiosarcomas are usually secondary tumours, and only few primary cases have been encountered. We report a unique primary case of epithelioid angiosarcoma arising in the spleen in a male patient 55-year-old and presented to our hospital as a medical emergency with acute abdomen and haemorrhagic ascitis. CT revealed splenic focal lesion and suggested that this abdominal haemorrhage was due to ruptured splenic haemangioma, thus abdominal exploration and splenectomy were done. The histopathological examination showed an infiltrating ill-defined growth formed of high grade epithelioid cells arranged in sheet-like growth pattern, with occasional papillary appearance. The presence of rudimentary vascular channels lined by epithelioid endothelial cells with occasional intraluminal erythrocytes suggested vascular tumour origin. The neoplastic cells showed diffuse expression of CD31 together with focal expression of cytokeratin (CK) and CD34. Because of its epithelioid morphology and unmistakable positivity for CK, this case may be easily misdiagnosed as a metastatic carcinoma, which is not uncommon finding in the spleen. Epithelioid angiosarcoma is a rare type of vascular tumour in the spleen, which co-expresses vascular and epithelial markers making its distinction from metastatic carcinoma is sometimes difficult.

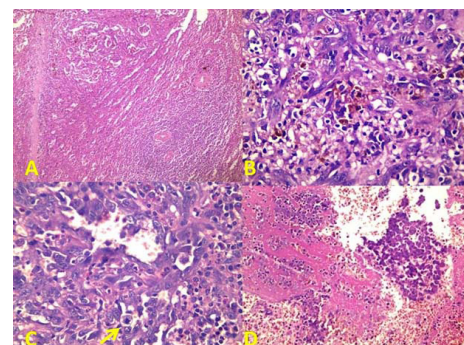
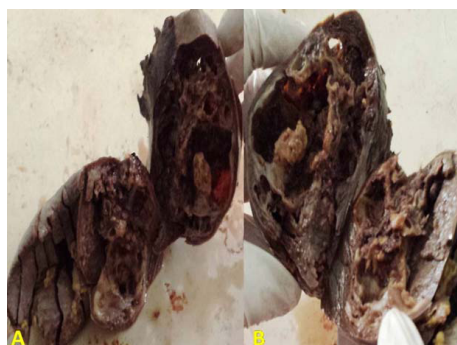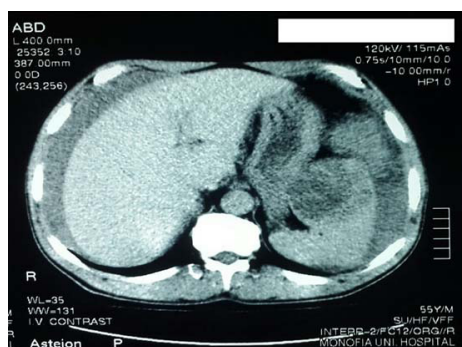
**Keywords:** CD31, CD34, Cytokeratin, Immunohistochemistry

## CASE REPORT

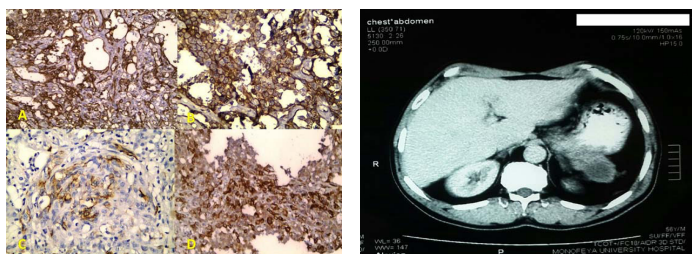
A 55-year-old male presented to the Emergency Department of Faculty of Medicine Menofiya University with acute abdomen and abdominal enlargement. Physical examination revealed severe tenderness in the left upper abdominal quadrant and haemodynamic instability (pallor and hypotension); the reported medical history was unremarkable up to the day before admission. An abdominal ultrasound showed a large quantity of intraperitoneal haemorrhagic fluid together with splenic focal lesion measured 62x45 mm with heterogeneous echo pattern in average sized spleen. These findings were confirmed by an abdominal computed tomography (CT) scan, which further demonstrated haemorrhage originating from ruptured splenic heterogeneous parenchymal lesion showing varying degrees of contrast enhancement and assuming a possibly of splenic haemangioma [Table/Fig-1]. Laparotomy revealed an actively bleeding spleen; splenectomy was done for the purpose of both diagnosis and therapy. Grossly, the spleen measured 12x9x6 cm, with preserved notch. A visible partially solid and partially cystic haemorrhagic splenic focal lesion measured 6x4x3 cm was detected [Table/Fig-2a,b]. The microscopic examination of the splenic lesion demonstrated an ill defined infiltrating malignant growth formed of epithelioid cells arranged in sheets, small nests, cords and rudimentary vascular channels with focal papillary areas

[Table/Fig-3]. These rudimentary vascular channels raised the suspicion for angiosarcoma. Unlike normal vascular channels, these neoplastic channels are irregular in shape, freely intercommunicate with one another in a sinusoidal fashion, and infiltrate the surrounding tissues in a destructive fashion. Those neoplastic cells were large rounded with moderate amount of cytoplasm, large vesicular nuclei and prominent nucleoli. The cells also featured high grade anaplasia together with frequent mitoses [Table/Fig-3]. On immunohistochemical examination, the neoplastic cells showed strong positive immunostaining for CD31 and focal positivity for CD34. The tumour cells also exhibited focal but strong positivity for CK and negative immunostaining for EMA and SMA [Table/Fig-4].

Postoperative CT scan of the abdomen, pelvis, and chest was performed owing to the highly metastatic potential of this tumour and to ensure the primary origin of the tumour and to verify absence of residual lesions, metastatic foci or ascitis. The patient received adjuvant chemotherapy (paclitaxel 6 cycles). At the end of treatment re-evaluation by CT revealed newly developed well defined lung nodule (2x2 cm) and involvement of surgical bed in relation to pancreatic tail with a peripheral enhancing lesion measured 4x4x3 cm suggesting both distant spread and local recurrence [Table/Fig-5]. The patient started second line chemotherapy (ifosfamide/doxorubicin) for 3 cycles followed by CT chest, abdomen and



**[Table/Fig-1]:** CT abdominal cut showing a heterogeneous splenic lesion and ascitis. **[Table/Fig-2a & b]:** An average sized spleen exhibiting partially solid partially cystic splenic mass. **[Table/Fig-3]:** a) An ill defined malignant growth infiltrating the splenic parenchyma; b) Sheets of epithelioid tumour cells with rudimentary vascular channel formation; c) Pleomorphic cells featuring vesicular nuclei, prominent nuclei & mitosis (arrow); d) Tumour cell necrosis. (Haematoxylin & eosin a) X40, b) X200, c) X400 & D X 100)



**[Table/Fig-4]:** Splenic epithelioid angiosarcoma with diffuse strong immunostaining for CD31 (a&b), focal positivity for CD34 (c) CK (d) (a&d X200, b&c X400)

**[Table/Fig-5]:** Follow up CT after splenectomy and chemotherapy showing a mass at the surgical bed infiltrating the stomach.

pelvis with contrast, which showed resolution of the previous lung nodule and stationary course of the splenic bed mass necessitating administration of more three cycles of ifosfamide/doxorubicin and new imaging was requested. Unfortunately, the patient presented to the Emergency Department with severe haematemesis and melena, he was submitted to blood transfusion and upper gastrointestinal tract endoscopy, which showed large gastric highly vascular mass at greater curvature with ulcerative bleeding surface. Triphasic CT abdomen and pelvis with contrast revealed greater curvature soft tissue lobulated mass (8x7x6 cm) in continuity with splenic bed mass, mostly direct tumour infiltration, and multiple well defined hypodense hepatic focal lesions, the largest measured 4x4.5 cm. The patient will be planned for palliative radiotherapy to control bleeding then further systemic treatment may be considered.

## DISCUSSION

Primary splenic angiosarcoma is a rare disease, firstly described in 1879, mostly as case reports [1]. Angiosarcoma is the most common primary non-lymphoid malignant tumour of spleen [2] with an annual incidence of 0.14–0.25 per million [3]. This rare aggressive neoplasm has a high rate of metastasis and poor prognosis [1]. The diagnosis is usually difficult and late because the patient remains asymptomatic till the onset of massive intra-abdominal bleeding [2]. Most patients present at age 50 to 79 years with a slight male predominance but no genetic predisposition [3,4].

Arsenic, polyvinyl chloride and thorium dioxide were considered as established carcinogens for hepatic angiosarcomas, which were not reported for splenic angiosarcomas. Some reported haemangiomas and haemangioendotheliomas as precursor lesions to splenic angiosarcoma [4,5]. Others claimed other causes such as exposure to ionizing radiation [6] or chemotherapy for lymphoma [7]. An inert foreign body tumourigenesis has also been blamed [8]. None of these factors were present in ours.

Asymptomatic disease and splenic rupture with subsequent fatal haemorrhage are the main clinical manifestations of primary splenic angiosarcoma [3]. Symptoms are usually non-specific including left upper abdominal discomfort (75-83%), dizziness and weight loss (10-40%), as well as anaemia (75-81%) and thrombocytopenia (14-55%). Furthermore, fever was also seen in 10% of the patients with angiosarcoma [4,5,9]. The commonest sign during examination is splenomegaly (71%) followed by hepatomegaly [1]. Splenic rupture is the most serious manifestation of the disease and represents 13% to 32% of cases [3]. The fact that most patients present with vague symptoms, which are not diagnostic and can be seen in many pathologic conditions, lead to late presentation of many cases until fatal splenic rupture occurs as in our case.

Definitive pre-operative diagnosis of splenic angiosarcoma remains challenging, as the radiologists cannot differentiate angiosarcoma from other benign and malignant splenic tumours using different imaging modalities. Splenic enlargement, the presence of a heterogeneous mass, punctuate or widespread calcification, also non enhancing areas due to necrosis or enhancement with a blush suggesting active bleeding, which are common radiologic findings

in splenic angiosarcoma can also be seen in lymphomas, splenic metastasis and other vascular lesions such as haemangiomas [10]. Moreover, biopsy is hazardous due to risk of bleeding and malignant seeding, thus splenectomy serves as an important diagnostic and therapeutic tool.

Spleen is distinctively a rare site of primary epithelioid angiosarcoma. Angiosarcoma with epithelioid histology has been more frequently reported in other sites such as skin [11], uterus [12], small intestine [13], lung [14], thyroid [15], central nervous system and orbit [16]. After an extensive literature search using key words such as “epithelioid angiosarcoma,” “spleen,” and “primary” in PubMed, Google and Ovid, we could identify only 7 cases of primary epithelioid angiosarcoma of the spleen. A clinico-pathologic series reported by Neuhauser et al., mentioned five cases of primary epithelioid angiosarcoma of spleen [5]. The sixth and seventh cases were reported by Keymeulen et al., and Cokelaere as a result of inert foreign body [8, 17]. Epithelioid morphology was mentioned as cellular feature intermixed with papillary and spindle cell morphology in a series of Falk et al., who studied 40 cases of splenic angiosarcoma, none of them could be designated as epithelioid type [4].

Under the microscope, epithelioid angiosarcoma is seen predominantly or exclusively formed of large, rounded malignant “epithelioid” cells with abundant amphophilic or eosinophilic cytoplasm and round to irregular vesicular nuclei with variably accentuated nucleoli. Those tumour cells express high nuclear grade and appeared arranged in sheets, nests, cords or rudimentary vascular channels. Extensive areas of haemorrhage and necrosis are frequently encountered [5].

Poorly differentiated forms of angiosarcoma are difficult to be recognized, which confirm the importance of immunohistochemistry in the diagnosis of such cases. Angiosarcomas express the usual vascular antigens such as von Willebrand factor, CD31, and CD34 in a variable degrees [18]. In our case, the tumour cells like all vascular tumours showed strong diffuse positivity for CD31, but focal positivity for CD34. CD31 is considered as a high specific and sensitive endothelial marker since it is positive in approximately 90% of angiosarcomas of all types [19,20]. On the other hand, there was a controversy about CD34 expression in epithelioid angiosarcoma with complete negativity for this antigen in reported cases of many organs [21,22] including breast [18], while strong positivity was reported in a pulmonary case [23]. The current case exhibited focal but strong positivity for CK. CK was performed in our case because the clinicians suggested that metastatic carcinoma could be one of the differential diagnoses. Approximately 30% to 50% of epithelioid angiosarcomas are positive for cytokeratin, rarely diffusely but they are negative for EMA (as seen in our case) [21]. Thus, we cannot rely alone upon Ck as an absolute discrimination tool between angiosarcoma and carcinoma [24].

Epithelioid angiosarcoma should be differentiated from non mesenchymal epithelioid mimickers as carcinoma, epithelioid malignant mesothelioma, and large cell non-Hodgkin lymphomas by using epithelial, mesothelial and lymphoma markers, respectively [21]. The great pleomorphism, frequent mitoses, solid growth pattern and necrosis could differentiate epithelioid angiosarcoma from epithelioid haemangioma and epithelioid haemangioendothelioma, where the aforementioned criteria were in favour of the diagnosis of angiosarcoma [24].

Angiomatous variant of epithelioid sarcoma may simulate epithelioid angiosarcoma at the level of morphology and CK expression, however, angiosarcoma is more pleomorphic and usually expresses CD31 and factor VIII [18].

Primary splenic angiosarcoma is a very aggressive neoplasm with poor prognosis due to its very high frequency of metastasis. The rate of metastasis is reported to be 69-100%. The main metastatic sites are the liver (89%), lung (78%), lymph nodes (56%), and bone

(22%) [25]. Splenic rupture represents the worst prognostic factor for survival, as most patients exhibit an increased risk of peritoneal dissemination together with direct implantation and haematogenous spread. This can appear clearly in the rapid progression of our case. Also, splenectomy when performed before rupture of the organ is usually accompanied by better survival rates [4]. Other independent prognostic factors include mitotic counts, tumour size and mode of treatment [26] as well as the thick capsule of the tumour [27].

Splenectomy is the treatment of choice for this neoplasm. The use of adjuvant treatment (chemotherapy and radiotherapy) is of controversy as no statistically significant correlation between survival and non-surgical treatment has been rendered [28]. Single agent chemotherapy such as paclitaxel or docetaxel is recommended for management of angiosarcoma, while combination regimens with anthracycline based chemotherapy are used for soft tissue sarcoma subtypes with non specific histologies [29,30].

## CONCLUSION

We describe a rare and aggressive case of primary splenic angiosarcoma of epithelioid histology; in which the clinical and radiological diagnosis is challenging. Epithelioid angiosarcoma is a rare type of splenic vascular tumour, which co-expresses vascular and epithelial markers making distinction from metastatic carcinoma is sometimes difficult.

## REFERENCES

- [1] Badiani R, Schaller G, Jain K, Swamy R, Gupta S. Angiosarcoma of the spleen presenting as spontaneous splenic rupture: A rare case report and review of the literature. *Int J Surg Case Rep.* 2013;4:765-67.
- [2] Shukla M, Basu S, Shukla VK, Kumar M. Fever, anaemia, and splenomegaly: A rare presentation of splenic angiosarcoma. *Indian J Med Paediatr Oncol.* 2011;32:230-32.
- [3] Manouras A, Giannopoulos P, Toufektzian L, Markogiannakis H, Lagoudianakis EE, Papadima A, et al. Splenic rupture as the presenting manifestation of primary splenic angiosarcoma in a teenage woman: a case report. *J Med Case Rep.* 2008;2:133.
- [4] Falk S, Krishnan J, Meis JM. Primary angiosarcoma of the spleen. A clinicopathologic study of 40 cases. *Am J Surg Pathol.* 1993;17:959-70.
- [5] Neuhauser TS, Derringer GA, Thompson LD, Fanburg-Smith JC, Miettinen M, Saaristo A, et al. Splenic angiosarcoma: a clinicopathologic and immunophenotypic study of 28 cases. *Mod Pathol.* 2000;13:978-87.
- [6] Sordillo EM, Sordillo pp, Hajdu SI. Primary haemangiosarcoma of the spleen: report of four cases. *Med Pediatr Oncol.* 1981;9:319-24.
- [7] Zwi LJ, Evans DJ, Wechsler A L, Catovsky D. Splenic angiosarcoma following chemotherapy for follicular lymphoma. *Hum Pathol.* 1986;17:528-30.
- [8] Keymeulen K, Dillemans B. Epithelioid angiosarcoma of the splenic capsule as a result of foreign body tumourigenesis. A case report. *Acta Chir Belg.* 2004;104:217-20.
- [9] Autry JR, Weitzner S. Haemangiosarcoma of spleen with spontaneous rupture. *Cancer.* 1975;35:534-39.

- [10] Falk S, Stutte HJ, Frizzera G. Littoral cell angioma. A novel splenic vascular lesion demonstrating histiocytic differentiation. *Am J Surg Pathol.* 1991;15:1023-33.
- [11] Mobini, N. Cutaneous epithelioid angiosarcoma: a neoplasm with potential pitfalls in diagnosis. *J Cutan Pathol.* 2009;36:362-69.
- [12] Olawaiye AB, Morgan JA, Goodman A, Fuller AF, Penson RT. Epithelioid angiosarcoma of the uterus: a review of management. *Arch Gynecol Obstet.* 2008;278:401-4.
- [13] Al Ali J, Ko HH, Owen D, Steinbrecher UP. Epithelioid angiosarcoma of the small bowel. *Gastrointest Endosc.* 2006;64:1018-21.
- [14] Pandit SA, Fiedler PN, Westcott JL. Primary angiosarcoma of the lung. *Ann Diagn Pathol.* 2005;9:302-04.
- [15] Fulciniti F, Di mattia D, Bove P, Mastro AA, De Chiara A, Botti G, et al. Fine needle aspiration of metastatic epithelioid angiosarcoma: a report of 2 cases. *Acta Cytol.* 2008;52:612-18.
- [16] Fernandes AL, Ratilal B, Mafra M, Magalhaes C. Aggressive intracranial and extra-cranial epithelioid haemangioendothelioma: a case report and review of the literature. *Neuropathology.* 2006; 26:201-05.
- [17] Cokelaere K, Vanvuchelen J, Michielsen P, Scirot R. Epithelioid angiosarcoma of the splenic capsule Report of a case reiterating the concept of inert foreign body tumourigenesis. *Virchows Arch.* 2001;438:398-403.
- [18] Muzumder S, Das P, Kumar M, Bhasker S, Sarkar C, Medhi K, et al. Primary epithelioid angiosarcoma of the breast masquerading as carcinoma. *Curr Oncol.* 2010;17: 64-69.
- [19] Mills SE, Gaffey MJ, Watts JC, Swanson PE, Wick MR, Livolsi VA, et al. Angiomatoid carcinoma and 'angiosarcoma' of the thyroid gland. A spectrum of endothelial differentiation. *Am J Clin Pathol.* 1994;102:322-30.
- [20] Goh SG, Chuah KL, Goh HK, Chen YY. Two cases of epithelioid angiosarcoma involving the thyroid and a brief review of non-Alpine epithelioid angiosarcoma of the thyroid. *Arch Pathol Lab Med.* 2003;127: E70-73.
- [21] Sajji E, Guillou L, Hornick J. Epithelioid and epithelial like tumours, in Practical Soft Tissue Pathology: A Diagnostic Approach, Hornick J, Editor. 2013, Elsevier Health Sciences, p p. 182.
- [22] Pagni F, Leone BE, Ronchi S, Sartori P, Corti, L, Maggioni D. Multicentric CD34 negative epithelioid angiosarcoma of the digestive system. *Acta Gastroenterol Belg.* 2012;75:466.
- [23] Ozcelik C, Onat S, Yaldiz M, Ozcelik Z. Primary epithelioid angiosarcoma of the lung presenting as pulmonary haemorrhage. *Asian Cardiovasc Thorac Ann.* 2006;14:69-71.
- [24] Weiss S, Lasota J, Miettinen M. Angiosarcoma of soft tissue, in WHO classification of tumours. Pathology and Genetics of Tumours of Soft Tissue and Bone, Fletcher C, Unni K, Mertens F, Editors. 2002, International Agency for Research on Cancer (IARC), pp. 175-177.
- [25] Hara T, Tsurumi H, Kasahara S, Ogawa K, Takada J, Imai K, et al. Long-term survival of a patient with splenic angiosarcoma after resection, high-dose chemotherapy, and autologous peripheral blood stem cell transplantation. *Intern Med.* 2010;49:2253-57.
- [26] Naka N, Ohsawa M, Tomita Y, Kanno H, Uchida A, Myoui A, et al. Prognostic factors in angiosarcoma: a multivariate analysis of 55 cases. *J Surg Oncol.* 1996;61:170-76.
- [27] Hsu JT, Chen HM, Lin CY, Yeh CN, Hwang TL, Jan YY, et al. Primary angiosarcoma of the spleen. *J Surg Oncol.* 2005;92:312-16.
- [28] Hamid KS, Rodriguez JA, Lairmore TC. Primary splenic angiosarcoma. *JLSL.* 2010;14:431-35.
- [29] Penel N, Bui BN, Bay JO, Cupissol D, Ray-Coquar I, Piperno-Neumann S, et al. Phase II trial of weekly paclitaxel for unresectable angiosarcoma: the ANGIOTAX Study. *J Clin Oncol.* 2008;26:5269-74.
- [30] Mehren M, Randall RL, Benjamin RS, et al. NCCN clinical practice guidelines in oncology (soft tissue sarcoma), 2015.

### PARTICULARS OF CONTRIBUTORS:

1. Lecturer, Department of Pathology, Menoufia University, Shebin El Kom, Egypt.
2. Professor, Department of Pathology, Menoufia University, Shebin El Kom, Egypt.
3. Professor, Department of Pathology, Menoufia University, Shebin El Kom, Egypt.
4. Lecturer, Department of Pathology, Menoufia University, Shebin El Kom, Egypt.
5. Lecturer, Department of Oncology, Menoufia University, Shebin El Kom, Egypt

### NAME, ADDRESS, E-MAIL ID OF THE CORRESPONDING AUTHOR:

Dr. Asmaa Gaber Abdou,  
Lecturer, Department of Pathology, Faculty of Medicine, Menofiya University, Shebein Elkom, Egypt.  
E-mail : Asmaa\_elsaidy@yahoo.com

FINANCIAL OR OTHER COMPETING INTERESTS: None.

Date of Submission: **Sep 24, 2015**

Date of Peer Review: **Oct 29, 2015**

Date of Acceptance: **Nov 18, 2015**

Date of Publishing: **Jan 01, 2016**